

Lingual Frenectomy and Surgical Techniques: A Short-Review

Open Access Journal of Dental and Oral Surgery (OAJDOS)

Volume 3 Issue 2, 2022

Article Information

Received date : May 13, 2022

Published date: June 20, 2022

*Corresponding author

Carlos M Cobo Vázquez, Associate Dentist, Department of Stomatology and Dentistry, Gregorio Marañón University General Hospital, Spain

Keywords

Lingual Frenectomy; Laser Frenectomy; Ankyloglossia; Lingual Frenulum

Distributed under Creative Commons
CC-BY 4.0

Adriana Castro Calderón¹, Carlos M Cobo Vázquez^{2,3*}, Luis Sánchez Labrador⁴, Luis Miguel Sáez Alcaide⁴, Juan López Quiles⁵ and Cristina Meniz García⁵

¹Oral Surgery and Implantology Master Student, Department of Clinical Specialities, Faculty of Dentistry, Complutense University of Madrid, Madrid, Spain

²Associate Dentist, Department of Stomatology and Dentistry, Gregorio Marañón University General Hospital, Spain

³Associate Professor, Department of Clinical Specialities, Faculty of Dentistry, Complutense University of Madrid, Spain

⁴University Professor, Department of Clinical Specialities, Faculty of Dentistry Complutense University of Madrid, Madrid, Spain.

⁵Titular Professor, Department of Clinical Specialities, Faculty of Dentistry, Complutense University of Madrid, Spain

Summary

Lingual frenectomy techniques are surgical correction procedures for frenulum defects that seek to restore the functionality of the affected area by removing the anatomical fold using manual surgical instruments or laser [1].

Objective: To describe the different lingual frenectomy techniques reported in the literature, recurrences or complications of the surgical techniques, and to find out at what age surgical treatment is preferable.

Materials and methods: Systematic review of the literature that managed to identify studies in order to gather information on lingual frenectomy techniques, the data corresponded to the results of published academic articles.

Results: Describe each of the techniques reported in the literature (conventional and laser) and whether they had limitations.

Conclusion: Greater predictability in the treatment, reduced risks in the surgical act, reduced work time and faster patient recovery.

Introduction

Ankyloglossia is a congenital disorder characterised by a short lingual frenulum. Kotlow classified ankyloglossia into different categories, where he assessed the free tongue, i.e. the distance between the insertion of the frenulum on the ventral side to the tip of the tongue [2]. It can also be defined as an embryological anatomical malformation of the tongue, characterised by an abnormally short and thick lingual frenulum with restricted tongue movement. The lingual frenulum is a membranous fold of mucosal tissue, which connects the ventral surface of the tongue to the floor of the mouth on one side and the basal bone of the mandible on the other side. In some individuals, the frenulum fibers adhere to the tip of the tongue, restricting its physiological movements. It is commonly seen in neonates with an incidence rate of about 5% [3]. Normal free tongue: greater than 16 mm

Class I mild ankyloglossia: 12 to 16 mm

Class II moderate ankyloglossia: 8 to 11 mm

Class III severe ankyloglossia: 3 to 7 mm

Class IV complete ankyloglossia: less than 3 mm.

Diagnosis

The limitation of movement is assessed clinically by asking the patient to make protrusion and elevation movements of the tongue, where the "heart-shaped" tongue can be observed. To achieve a good diagnosis, the following must be considered in the examination: the patient cannot touch the labio-mental groove or the retroincisive papilla due to the limitation of tongue movement. Due to this anomaly present in the lingual frenulum it may be related to inflammation and lingual gingival recessions in the central incisors. The lingual frenulum has a firm tendinous attachment to the floor of the mouth and a fibrous band attached to the alveolar process. In this area it is related to important anatomical structures, the duct of Wharton which is responsible for draining saliva from the submaxillary gland and its outlet caruncle, the duct of Rivinus which is responsible for draining saliva from the sublingual gland, the lingual nerve and the sublingual vessels. It is important to mention that ankyloglossia in infants can cause various problems, such as problems with breastfeeding, nausea, choking, vomiting and behavioural changes. In addition, it can cause children to have difficulty pronouncing consonants such as "T", "D", "N" and "L".

The altered chewing and swallowing pattern in individuals with ankyloglossia even affects the coordination of the jaw muscles during speech and results in the development of habits such as mouth breathing, aerophagia and forward tongue position [4]. The risk of developing Class III malocclusions together with reduced maxillary growth and mandibular prognathism is increased in children with ankyloglossia. Therefore, surgical correction of the aberrant lingual frenulum insertion is essential to overcome these mechanical limitations and functional challenges. The most common method of correcting ankyloglossia is by surgical excision of the aberrant frenal junctions by a process known as frenotomy, frenectomy

or frenuloplasty [5]. A surgical incision with a scalpel, electrocautery or soft tissue lasers is commonly used for lingual frenectomy.

Material and Methods

Inclusion Criteria:

- Studies in English or Spanish.
- Publication deadline 5 years prior to the current year 2020.

Exclusion Criteria

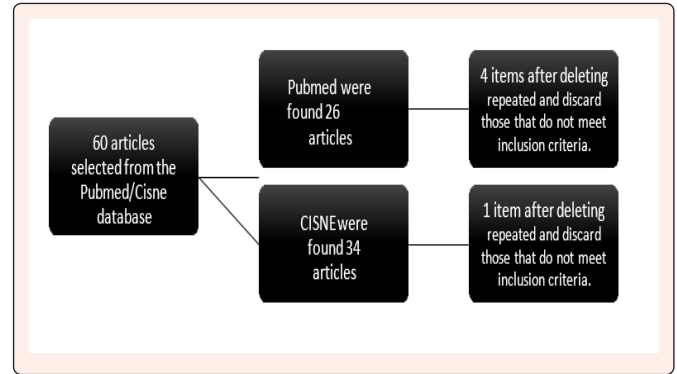
- Studies prior to 2015.
- Studies that do not mention surgical techniques or surgical or post-surgical complications associated with lingual frenectomy.
- Studies that do not exclusively mention lingual frenectomy or ankyloglossia.
- In vitro studies.

A bibliographic search was carried out in the PUBMED/CISNE electronic database. The keywords used were: Lingual frenectomy, surgical techniques, Ankyloglossia. In addition, the Boolean operators “AND” “OR” were used, in the following forms:

- Lingual Frenectomy “AND” surgical techniques.
- Lingual Frenectomy “OR” Ankyloglossia “OR” Lingual Frenulum “AND” surgical techniques.

Results

Using the keywords and Boolean operators mentioned above, 60 articles were obtained from the Pubmed and Cisne databases. We excluded all articles published prior to 2015, duplicate articles within the databases and among them, in vitro studies, which included labial frenectomies, surgeries for other purposes (orthodontic, orthognathic surgery, implants, reconstructions) and which included adult patients.



Data Extraction Table

Author	Target	Type of study	Sample	Surgical Technique	Results/ conclusions
Komori et al. [6]	Suggest laser treatment for the management of lingual frenectomy in paediatric patients	Retrospective study	27 patients with an average age of 6 years.	CO ₂ laser	Positive result on the usefulness of CO ₂ laser for the surgical procedure of lingual frenectomy. Useful, simple and safe treatment.
Ferrés-Amat et al. [7]	Present the action protocol for the treatment of ankyloglossia.	Descriptive study	Healthy patients aged 4-14 years	Rhomboid frenectomy, myotomy and myofunctional rehabilitation (pre- and postintervention).	101 lingual frenectomies were performed and resulted in the tongue being freed, where it can reach its highest point and has a completely free movement. Improvements with myofunctional rehabilitations 1 week post-surgery.
Garrocho Rangel et al. [8]	To review the current knowledge on laser treatment of ankyloglossia in children and to report a case of a paediatric patient treated with laser.	Systematic review	17 articles involving patients under 14 years of age. Case report: patient 8.5 years of age.	Diode laser, CO ₂ laser, Erbium Laser, infrared laser.	Laser increases predictability compared to conventional scalpel methods. Reduces post-operative discomfort, functional and masticatory complications Reduces the risk of conventional surgery in terms of injury to the submandibular gland ducts. Avoid risk post-suture of Warton’s canal, damage to the lingual nerve or sublingual blood vessels, numbness of the tongue tip.
Ramoser, G. et al. [9]	To assess clinical manifestations and	Retrospective study	329 patients (295 infants aged 0-12 months and 34 children over 12 months) from the Paediatric Clinic of the Medical University of Innsbruck between February 2011 and February 2017.	Frenectomy with scissors	-There is a male predominance among patients, m=58% and f=42%. There is a male predominance among patients, m=58% and f=42%. -Among infants the median age of intervention is 6 weeks and among children 4 years. Regarding the insertion point, 7% is anterior, 67% is posterior and 26% is unclassified. Of the 329 cases, the parents of 141 (43%) patients completed short-term questionnaires. Of these 121 (86%) showed improvement, 19 (13%) no change and 1 (1.4%) worsened. Of the 329 patients, 197 interventions were eligible for long-term assessment, of which 164 returned the questionnaire. 135 (82%) had improvement, 27 (16%) no change and 2 (1.2%) worsened, but the reported sign is considered short-term and secondary to recovery, which did not require treatment. -Additionally, mothers reported decreased pain during breastfeeding, regulation of milk production and improved bottle sucking by the children, as well as improved tongue mobility and decreased milk leakage at the corner of the mouth. Children’s speech articulation improved by 12%. 81 cases (25%) answered short-term and long-term questionnaires with concordant answers.



Varadan et al. [10]	To determine the surgical and postsurgical complications in lingual frenectomy.	Systematic review	20 articles met the inclusion and exclusion criteria	Not mentioned	Complications -Bleeding or haemorrhage. -Retention cyst or ranula formation -Formation of sublingual haematoma. -Development of sublingual and submandibular space infection -Reinsertion or recurrence of the insertion of the braces. -Development of a new speech disorder. -Numbness and paraesthesia of the tongue and surrounding soft tissues.
---------------------	---	-------------------	--	---------------	--

Discussion

With regard to surgical techniques.

Most of the articles highlight positive results, regardless of the surgical technique used. Laser (CO₂) techniques stand out for reducing the risk of postoperative pain and sublingual oedema or haematoma, as well as the risk of choking and asphyxia; it also reduces bleeding and postoperative discomfort for patients. With respect to the Erbium Laser, it is considered ideal for paediatric patients, due to the control of the operative field and because it makes clean incisions, facilitating haemostasis. In relation to the laser technique and its advantages over the traditional scalpel technique, it is mentioned that they can be ideal for use in paediatric patients, as they speed up recovery and reduce trauma for patients. This is because they reduce surgical risks, such as injury to the sublingual and submandibular glands, Wharton's duct, nerve endings in the floor of the mouth, and also, compared to the conventional technique, they prevent obstruction of the Wharton's duct or injury to blood vessels during suturing. It is also important to mention that it reduces the work time from half an hour, as a frenectomy can take using the conventional technique, to approximately 10 minutes. The disadvantage of the laser is its higher monetary value over the conventional technique and also the knowledge of the corresponding equipment on the part of the practitioner.

With regard to symptoms

In infants, there is a substantial improvement in breastfeeding difficulties, improving the sucking capacity of the breast and reducing discomfort for the mother, as well as reducing the loss of milk between the lips; it also facilitates bottle feeding. On the other hand, it favours phonation in most cases. Because of the early need to resolve breastfeeding-related problems, quick and efficient decision making is necessary. Parental commitment to monitoring and follow-up is essential. Due to the varied nature of the manifestations of ankyloglossia, the work of a multidisciplinary team is indispensable for the success of the procedures. The work of doctors, paediatricians, midwives, nurses, speech therapists, otolaryngologists and dentists, both in diagnosis and in treatment and recovery, is essential. All patients need post-surgical therapy to exercise tongue mobility and recover chewing or suckling function. These exercises are performed 3 to 5 times a day for 1 month. In this way, it was possible to demonstrate in the different studies, a post-surgical improvement in less time and with better future benefits for the paediatric patient.

Regarding complications

It should be noted that most studies do not highlight major complications. In some cases, these are due to the normal post-surgical recovery period. The percentage of patients with complications is around 3-14%. Most of these complications are due to scar tissue formation, which can lead to further phonation complications. Injuries to surrounding structures such as vessels, nerves and glands are rare, as are haematomas, bleeding and oedema of greater volume than expected. It is necessary for the surgical team to be knowledgeable about the procedure and the anatomy. The importance of follow-ups and the team in charge of post-surgical rehabilitation is also emphasised.

Conclusion

Early diagnosis and treatment of ankyloglossia is essential for the proper oral functional development of paediatric patients. Secondly, lingual frenectomy by laser surgery provides a more effective and comfortable treatment for both the paediatric patient and the paediatric dentist compared to traditional scalpel methods. However, there is a great need for further research by conducting high-quality studies, including randomised controlled clinical trials with adequate sample sizes, comparing the various laser beam approaches with conventional surgical techniques, including cost-benefit analyses, for lingual frenectomy in neonates, infants, children and young adolescents. It is also important to note that myofunctional rehabilitation plays an important role, starting one week before surgery, the aim of this protocol is for the patient to learn the exercises without pain. The results of these studies show that the surgical technique of frenectomy improves the patient's tongue mobility. If reinforced with rehabilitation exercises and good patient cooperation, the results are excellent. Finally, multidisciplinary work is indispensable for the detection, treatment and rehabilitation of patients, as well as the cooperation of parents.

References

- Tomar N, Bansal T, Bhandari M, Sharma A (2013) The perio-esthetic-restorative approach for anterior rehabilitation. *J Indian Soc Periodontol* 17(4): 535-538.
- Cuestas G, Demarchi V, Martínez MP, Razetti J, Boccio C (2014) Surgical treatment of short lingual frenulum in children. *Arch Argent Pediatr* 112(6): 567-70.
- Johnson RV (2006) Tongue-tie exploding the myths. *Infant* 2(3): 96-99.
- Kloars T (2007) Familial ankyloglossia (tongue-tie). *Int J Pediatr Otorhinolaryngol* 71(8): 1321-1344.
- Suter VGA, Bornstein MM (2009) Ankyloglossia: facts and myths in diagnosis and treatment. *J Periodontol* 80(8): 1204-1219.
- Komori S, Matsumoto K, Matsuo K, Suzuki H, Komori T (2017) Clinical Study of Laser Treatment for Frenectomy of Pediatric Patients. *Int J Clin Pediatr Dent* 10(3): 272-277.
- Ferrés AE, Pastor VT, Ferrés AE, Mareque BJ, Prats AJ, et al. (2016) Multidisciplinary management of ankyloglossia in childhood. Treatment of 101 cases. A protocol. *Med Oral Patol Oral Cir Bucal* 21(1): e39-47.
- Garrocho RA et al. (2019) Treatment of ankyloglossia with dental laser in paediatric patients: Scoping review and a case report. *Eur J Paediatr Dent* 20(2):155-163.
- Ramoser G, Guóth GM, Baumgartner SS, Zoeggeler T, Scholl BS, et al. (2019) Frenotomy for tongue-tie (frenulum linguae breve) showed improved symptoms in the short- and long-term follow-up. *Acta Paediatr* 108(10): 1861-1866.
- Varadan M, et al. (2019) Etiology and clinical recommendations to manage the complications following lingual frenectomy. A critical review. *J Stomatol Oral Maxillofac Surg* 120(6): 549-553.